Pathologic Separation of Chronic Hypersensitivity Pneumonitis From Fibrotic Connective Tissue Disease–associated Interstitial Lung Disease

Andrew Churg, MD, Joanne L. Wright, MD,† and Christopher J. Ryerson, MD‡*

Abstract: Chronic (fibrotic) hypersensitivity pneumonitis (HP) and fibrosing interstitial pneumonias associated with connective tissue disease (CTD-ILD) can be difficult to distinguish in biopsy specimens. To investigate features that might separate these entities, 2 pathologists blinded to the diagnoses reviewed 16 cases of chronic HP and 12 cases of CTD-ILD. Fifteen predefined parameters were examined by morphometric point counting, analysis/cm^2 of lung tissue, or presence/absence. Germinal centers were present in a minority of patients, but favored a diagnosis of CTD-ILD (7/12 CTD vs. 2/16 HP; odds ratio, 9.80 [95% confidence interval, 1.50-63.4]; $P = 0.02$). The number of lymphoid aggregates/cm^2 (4.4 ± 3.1 vs. 1.4 ± 1.0; $P = 0.001$), volume proportion of plasma cells (0.076 ± 0.058 vs. 0.031 ± 0.023; $P = 0.031$), and plasma cell: lymphocyte ratio (1.03 ± 0.71 vs. 0.35 ± 0.22; $P = 0.001$) were all significantly higher in CTD compared with HP. A diagnosis of HP was more common in the presence of peribronchiolar metaplasia (12/16 HP vs. 4/12 CTD; odds ratio, 6.00 [95% confidence interval, 1.15-31.2]; $P = 0.033$) and in patients with a greater fraction of bronchioles showing peribronchiolar metaplasia (0.41 ± 0.33 vs. 0.16 ± 0.27; $P < 0.001$). Number of fibroblast foci/cm^2, distribution of fibroblast foci, pattern of fibrosis, presence of giant cells/granulomas, and volume proportion of lymphocytes or eosinophils did not distinguish chronic HP from CTD-ILD. We conclude that no single morphologic measure definitively separates chronic HP from CTD-ILD lung biopsies, but numerous foci of peribronchiolar metaplasia favor HP, while the presence of germinal centers, large numbers of lymphoid aggregates, or a high plasma cell: lymphocyte ratio suggests CTD-ILD. Multidisciplinary discussion is often necessary for accurate classification inthis setting.

From the *Departments of Pathology, Vancouver General Hospital and University of British Columbia; †Departments of Pathology, St Paul's Hospital and University of British Columbia; and ‡Department of Medicine and Center for Heart Lung Innovation, University of British Columbia, Vancouver, BC, Canada.

Conflicts of Interest and Source of Funding: The authors have disclosed that they have no significant relationships with, or financial interest in, any commercial companies pertaining to this article.

Correspondence: Andrew Churg, MD, Department of Pathology, JPPN1401 Vancouver General Hospital, 910 W 10th Avenue, Vancouver, BC, Canada V5Z 1M9 (e-mail: achurg@mail.ubc.ca).

Copyright © 2017 Wolters Kluwer Health, Inc. All rights reserved.

Key Words: chronic hypersensitivity pneumonitis, connective tissue disease–associated interstitial lung disease, interstitial lung disease, interstitial pneumonitis with autoimmune features

(*Am J Surg Pathol* 2017;41:1403–1409)

The management of fibrotic interstitial lung disease (ILD) has evolved from a one-size-fits-all "try steroids" approach to a situation in which accurate diagnosis is required to identify the most appropriate therapy. Antifibrotic therapy (pirfenidone, nintedanib) is now recommended for patients with idiopathic pulmonary fibrosis,[1] while a variety of immunosuppressive medications are used for many other fibrosing interstitial pneumonias.[2–4] In addition, a diagnosis of chronic (ie, fibrotic) hypersensitivity pneumonitis (referred to hereafter as "HP") mandates a careful search for an antigen with the hope that avoiding further exposure may improve prognosis.[5]

The diagnosis of fibrotic ILD is frequently challenging, and ideally is carried out in the setting of a face-to-face multidisciplinary discussion (MDD).[6] Accurate pathologic contribution to the MDD can be problematic because the different types of ILD frequently have complex morphologic patterns that often have overlapping features. Surgical lung biopsies are often required to distinguish idiopathic interstitial pneumonias, HP, and subtle forms of connective tissue disease–associated ILD (CTD-ILD); however, the features of HP and CTD-ILD can overlap and there are conflicting claims about features that favor one diagnosis or the other. For example, HP commonly has a combination of subpleural and peribronchiolar fibrosis,[6–11] but CTD-ILD can have the same combination.[11] In addition, a recent review suggests that the presence of lymphoid aggregates favors CTD-ILD, particularly when germinal centers are present[11]; however, other reports indicate that this finding is also common in HP.[12] Similarly, plasma cells are often viewed as a feature of CTD-ILD,[11] but are also a frequent finding in HP.[12]

Previous studies that describe the pathologic features of HP and CTD-ILD are generally descriptive and do not provide specific data on the frequency of individual findings nor a mechanism for incorporating these findings into a pathologic gestalt. The objectives of

Copyright © 2017 Wolters Kluwer Health, Inc. All rights reserved.

this study were to quantify specific pathologic findings of HP and CTD-ILD, and to identify qualitative and quantitative features that might distinguish these diagnoses.

METHODS

Study Population

Patients with a diagnosis of either HP or CTD-ILD were identified from an ongoing clinical registry. All cases were reviewed between 2013 and 2016 in a face-to-face multidisciplinary conference that included ILD clinicians, chest radiologists, and lung pathologists. The study was approved by the University of British Columbia Committee on Human Ethics (H16-01399).

Clinical Features

Baseline features at the time of diagnosis (considered the date of surgical lung biopsy) were identified from the patient chart, including age, sex, and smoking history. Exposure history and CTD features were reviewed in all patients through a detailed clinical history and based on patient questionnaires. ILD-targeted medications used at the time of biopsy were recorded. Detailed physiological measurements were performed according to standard recommendations.[13,14]

Pathologic Features

Biopsies were reviewed by 2 experienced pulmonary pathologists (A.C., J.L.W.) who were blinded to both the original pathologist's impression and the MDD diagnosis. All biopsies had been inflated with formalin and allowed to fix at least overnight before sectioning. All of the biopsy slides from each case were initially reviewed and a slide considered to be representative of the findings in each lobe was selected for detailed study. Table 1 shows the pathologic features reviewed and the method of quantifying each feature. Areal measurements were determined based on review of the entire slide and expressed as features of interest/cm^2 of tissue.

Lymphoid aggregates were defined as circumscribed and typically rounded collections of lymphocytes with or without a germinal center. The volume proportions of plasma cells, lymphocytes, and eosinophils were determined by photographing five $\times 40$ microscopic fields from areas with the highest concentration of interstitial inflammation, with careful exclusion of lymphoid aggregates and germinal centers. The volume proportion of each cell type was then determined by point counting using a 280-point grid and determining the number of points that fell on tissue, airspace, or the cell of interest.[15] The distribution of fibroblast foci was recorded as subpleural (peripheral lobular), centrilobular (peribronchiolar), both, random, or absent. The distribution of fibrosis was recorded as subpleural (peripheral lobular), centrilobular (peribronchiolar), both subpleural and centrilobular (peribronchiolar), random, or diffuse (ie, in a nonspecific interstitial pneumonia pattern).

Statistical Analysis

Data are described as number (percent), mean ± SD, or median (interquartile range) as appropriate. The Fisher exact tests were used to determine the associations of dichotomous and categorical variables with the final diagnosis. The association of continuous variables with final diagnosis was determined by t test or Wilcoxon rank sum test. A 2-sided $P < 0.05$ was used to indicate statistical significance for all comparisons. All data were analyzed using STATA 11.2 (StataCorp, Texas) or SYSTAT (Systat Software Inc., San Jose, CA).

TABLE 1. Pathologic Features Examined and Quantification Methods

Features	Quantification Method
Peribronchiolar metaplasia	Present/absent
Peribronchiolar metaplasia	Fraction of bronchioles with associated peribronchiolar metaplasia
	Number/cm^2 of tissue
Germinal centers	Present/absent
	As a fraction of lymphoid aggregates
	Number/cm^2 of tissue
Lymphoid aggregates	Number/cm^2 of tissue
Volume proportion of plasma cells, lymphocytes, eosinophils	Morphometric point counting of each cell type
Plasma cell: lymphocyte ratios	Derived from the volume proportion data
Number of fibroblast foci	Number/cm^2
Location of fibroblast foci	Centrilobular, peripheral (subpleural), both centrilobular and peripheral, none
Location of interstitial fibrosis	Centrilobular (peribronchiolar), peripheral (subpleural), both centrilobular and peripheral, random, diffuse
Giant cells/granulomas	Present/absent

RESULTS

Clinical Features

The study cohort included 28 patients, including 16 with chronic HP and 12 with CTD-ILD (Table 2). The CTD-ILD population included 4 with undifferentiated CTD, 2 with systemic sclerosis, 1 with rheumatoid arthritis, 1 with primary Sjogren syndrome, and 4 who met criteria for interstitial pneumonia with autoimmune features (IPAF).[16] One patient with HP had an antigen identified; the absence of an identifiable antigen was a key factor in the decision to pursue a biopsy in the remaining patients. All patients were untreated at the time of biopsy,

TABLE 2. Patient Characteristics at Baseline

Variables	CTD-ILD (N = 12)	CHP (N = 16)
Age (SD) (y)	61 (13)	56 (13)
Male sex (n [%])	6 (50)	8 (50)
Smoking history		
Ever (n [%])	7 (58)	8 (50)
Pack-years (SD)	14 (18)	13 (22)
Pulmonary physiology		
FVC (% predicted)	69 (20)	64 (19)
FEV_1 (% predicted)	71 (19)	70 (22)
DLCO (% predicted)	48 (18)	49 (18)

Copyright © 2017 Wolters Kluwer Health, Inc. All rights reserved.

Copyright © 2017 Wolters Kluwer Health, Inc. All rights reserved.

except for 2 patients with HP who were on prednisone 2.5 mg daily and 1 patient with undifferentiated CTD who was on prednisone 35 mg daily. Median duration of follow-up after biopsy was 5.4 years, with 3 deaths (1 in HP, 2 in CTD-ILD) and 2 transplants (1 in HP, 1 in CTD-ILD).

Pathology Findings

The number of biopsied lobes per case ranged from 1 to 3, with a mean and median of 2. The mean tissue area of the combined biopsies for each case was 4.3 ± 2.0 cm^2 (median 4.5 cm^2). All biopsies showed interstitial fibrosis in various patterns. None of the pathologic features examined were confined to only CTD-ILD or HP.

Pathologic Features Favoring CTD-ILD

Germinal centers were more frequent in CTD-ILD than HP (7/12 vs. 2/16; odds ratio, 9.80 [95% confidence interval, 1.5-63.4]; $P = 0.02$) (Fig. 1A). The number of lymphoid aggregates/cm^2 was greater in CTD-ILD compared with HP (4.4 ± 3.1 vs. 1.4 ± 1.0; $P = 0.001$) (Fig. 1B). Germinal centers as a fraction of lymphoid aggregates was also higher in CTD-ILD versus HP (0.13 ± 0.17 vs. 0.02 ± 0.06; $P = 0.02$) (Fig. 1C). The volume proportion of plasma cells was greater in CTD-ILD than HP (0.076 ± 0.058 vs. 0.031 ± 0.023; $P = 0.03$), and the plasma cell: lymphocyte ratio was also significantly higher in CTD-ILD than HP (1.0 ± 0.7 vs. 0.35 ± 0.22; $P = 0.001$)

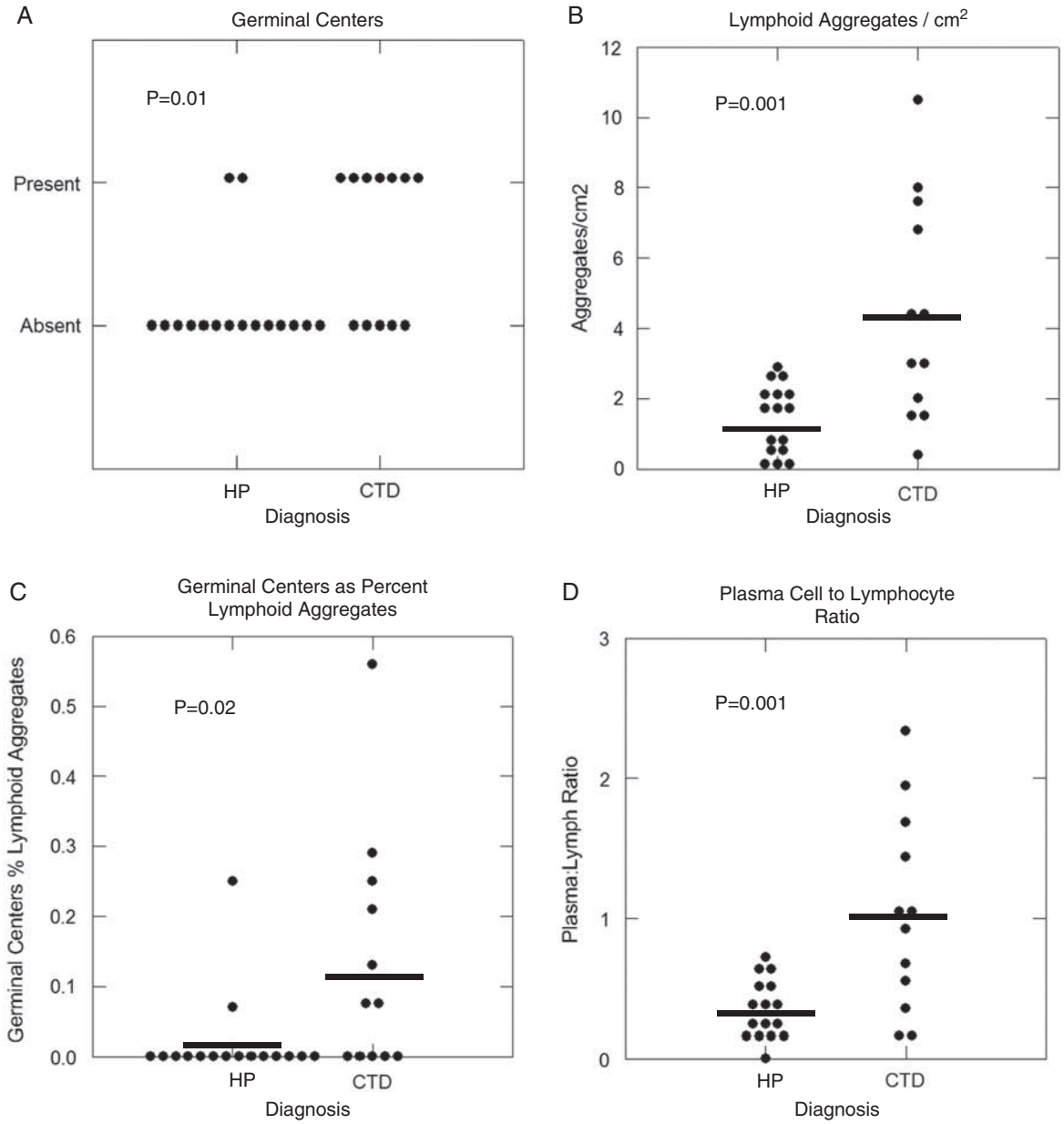

FIGURE 1. Features favoring a diagnosis of CTD-ILD. Germinal centers as a dichotomous variable (A); lymphoid aggregates/cm^2 (B); germinal centers as a percent of lymphoid aggregates (C); plasma cell to lymphocyte ratio (D).

Copyright © 2017 Wolters Kluwer Health, Inc. All rights reserved.

Copyright © 2017 Wolters Kluwer Health, Inc. All rights reserved.

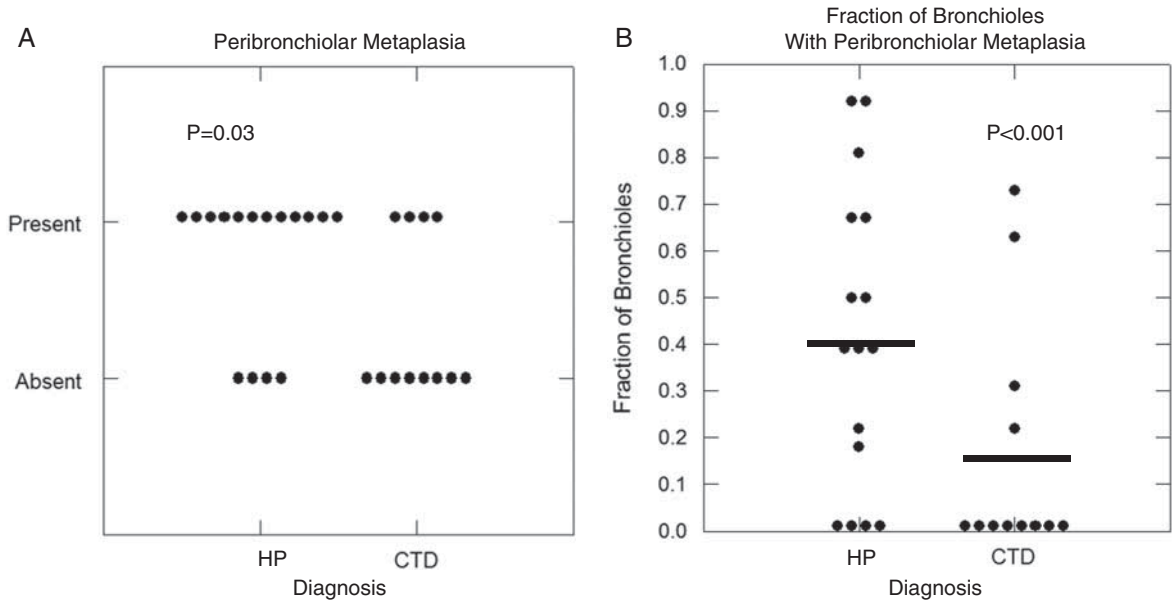

FIGURE 2. Features favoring a diagnosis of HP. Peribronchiolar metaplasia as a dichotomous variable (A); fraction of bronchioles with peribronchiolar metaplasia (B).

(Fig. 1D). All 6 patients with a plasma cell: lymphocyte ratio of ≥ 1 had CTD-ILD (odds ratio for HP, 0; 95% confidence interval, 0-0.29; $P = 0.003$).

Pathologic Features Favoring HP

Peribronchiolar metaplasia was the only feature more frequent in HP compared with CTD-ILD, measured as either a dichotomous present/absent variable (12/16 HP vs. 4/12 CTD-ILD; $P = 0.03$) (Fig. 2A), or as the fraction of bronchioles with associated peribronchiolar metaplasia (0.41 ± 0.33 vs. 0.16 ± 0.27; $P < 0.001$) (Fig. 2B). The number of foci of peribronchiolar metaplasia/cm^2 was nonsignificantly higher in HP compared with CTD-ILD (1.2 ± 1.3 vs. 0.54 ± 0.66; $P = 0.24$). The odds ratio for a diagnosis of HP in patients with any peribronchiolar metaplasia was 6.0 (1.2-31; $P = 0.03$). Patients with peribronchiolar metaplasia affecting $\geq 50\%$ of bronchioles had an odds ratio for HP of 2.3 (0.40-12.4; $P = 0.66$).

Pathologic Features that Did Not Discriminate Between HP and CTD-ILD

Neither the number of fibroblast foci/cm^2 (2.2 ± 2.3 in CTD-ILD vs. 3.2 ± 3.3 in HP, $P = 0.38$, Fig. 3A) nor the location of fibroblast foci (Fig. 3B) was different between groups. The volume proportion of lymphocytes (0.099 ± 0.060 in CTD-ILD vs. 0.12 ± 0.04 in HP, $P = 0.34$) and eosinophils (0.0031 ± 0.0064 in CTD-ILD vs. 0.00036 ± 0.00059 in HP, $P = 0.093$) were similar in both conditions. There was no difference in the proportion of patients with giant cells/granulomas (4/12 CTD-ILD vs. 9/16 HP, $P = 0.28$). There was no between-group difference in the highly variable location and pattern of interstitial fibrosis, including centrilobular (peribronchiolar) fibrosis only (2/12 vs. 3/16), subpleural/peripheral fibrosis only (2/12 vs. 0/16), both centrilobular (peribronchiolar) and subpleural fibrosis (5/12 vs. 12/16), and diffuse fibrosis resembling nonspecific interstitial pneumonia (2/12 vs. 0/16) (Fig. 3C). There were no differences in any measure between CTD-ILD patients with a defined connective tissue disease and those with IPAF (Table 3).

DISCUSSION

In this study we provide quantitative estimates of how much various biopsy findings favor chronic HP or CTD-ILD, which is increasingly recognized as a challenging pathologic distinction. Figure 4 illustrates the morphologic extremes within our cohort that are characteristic of HP and CTD-ILD; however, the visual dichotomy is not as clear in most cases. Our findings suggest that a diagnosis of CTD-ILD is more likely in patients with any germinal centers, high numbers of lymphoid aggregates/cm^2 of tissue (> 4), and a high plasma cell: lymphocyte ratio (1.0 or greater). A diagnosis of HP is more likely in patients with peribronchiolar metaplasia, measured either as a dichotomous variable or as a fraction of bronchioles with peribronchiolar metaplasia (≥ 0.5). However, all of these measures must be used with caution because there was no single pathologic feature that allowed an unequivocal diagnosis of either HP or CTD-ILD, with all examined parameters found in both conditions.

Some of our findings were surprising. For example, giant cells/granulomas are commonly used as a defining feature of HP,[7] but were found here in only 56% of HP patients and were also found in one third of CTD-ILD patients. A lack of giant cells/granulomas in HP has similarly been reported in another recent study.[17] Thus, although giant cells/granulomas may suggest a diagnosis of HP, there are inadequate positive and negative predictive

Copyright © 2017 Wolters Kluwer Health, Inc. All rights reserved.

Copyright © 2017 Wolters Kluwer Health, Inc. All rights reserved.

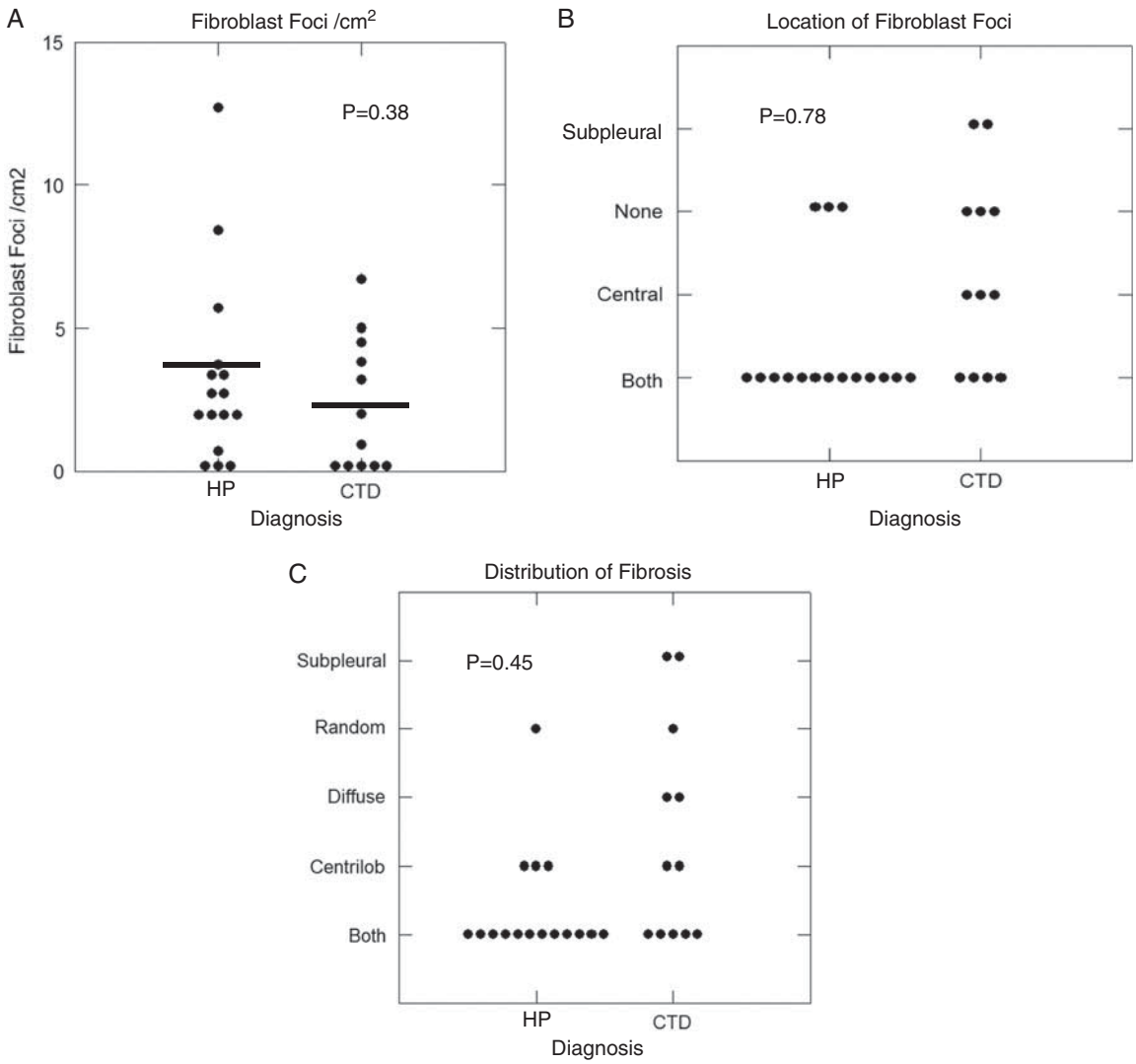

FIGURE 3. Features that do not favor either diagnosis. Fibroblast foci/cm^2 (A); location of fibroblast foci (B); distribution of fibrosis (C).

TABLE 3. Comparison of IPAF and Defined CTD Cases

Features	IPAF	Defined CTD
Peribronchiolar metaplasia	2/4	2/8
Fraction of airways with peribronchiolar metaplasia	0.34 ± 0.40	0.07 ± 0.13
Foci of peribronchiolar metaplasia/cm^2	0.60 ± 0.40	0.13 ± 0.25
Plasma cell: lymphocyte ratio	0.89 ± 0.99	1.10 ± 0.59
Volume proportion plasma cells	0.070 ± 0.033	0.080 ± 0.070
Volume proportion lymphocytes	0.13 ± 0.08	0.084 ± 0.048
Volume proportion eosinophils	0.002 ± 0.003	0.004 ± 0.008
Germinal centers	3/4	4/8
Lymphoid aggregates/cm^2	6.52 ± 3.35	3.40 ± 2.63
Fraction of lymphoid aggregates with germinal centers	0.25 ± 0.24	0.076 ± 0.101
Fibroblast foci/cm^2	1.67 ± 1.33	2.5 ± 2.6
Giant cells/granulomas	1/4	3/8

values to support its use in isolation when attempting to distinguish HP from CTD-ILD. Similarly, centrilobular (peribronchiolar) fibrosis (with or without peripheral fibrosis) is consistently reported as a feature of HP,[8–10] but was observed here in 7/12 CTD-ILD cases and 13/16 HP cases. Given the absence of single pathognomonic features, we also attempted to identify combinations of features that might help distinguish HP from CTD-ILD; however, these analyses were limited by our small sample size and exploratory analyses failed to show combinations of features that were better than any individual parameters.

It is often straightforward to make a diagnosis of CTD-ILD in patients with a clear underlying CTD that meets established criteria, and a surgical lung biopsy is typically not pursued in this situation. This is reflected in the high agreement ($\kappa = 0.73$) for the diagnosis of CTD-ILD in patients who did not undergo a surgical lung biopsy in a recent study that compared diagnostic agreement across

Copyright © 2017 Wolters Kluwer Health, Inc. All rights reserved.

Copyright © 2017 Wolters Kluwer Health, Inc. All rights reserved.

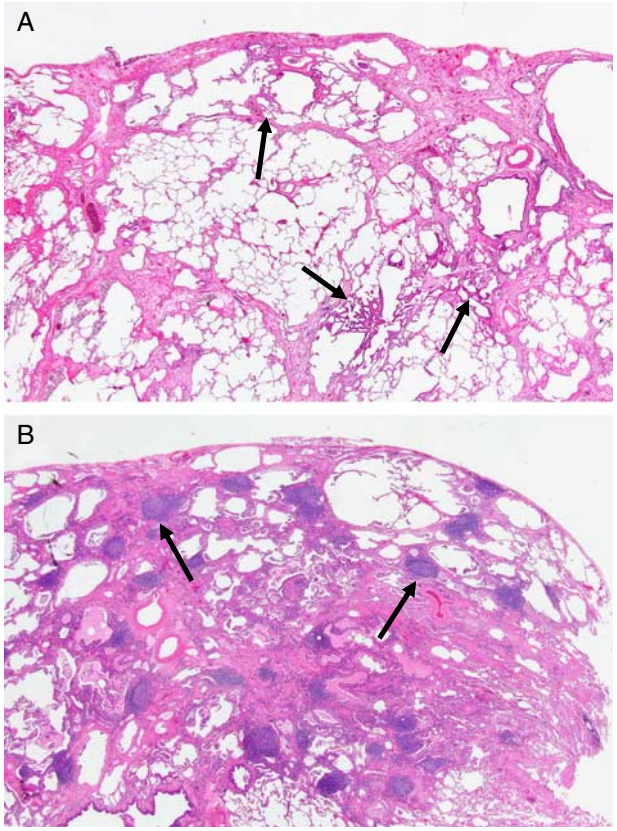

FIGURE 4. Morphologic extremes of HP and CTD-ILD. A, HP: micrograph showing no lymphoid aggregates or germinal centers, and there is prominent peribronchiolar metaplasia (arrows). B, CTD-ILD: micrograph showing no peribronchiolar metaplasia, but numerous lymphoid aggregates with frequent germinal centers (arrows).

7 experienced multidisciplinary groups.[18] In contrast, the lower diagnostic agreement for biopsied patients in this previous study illustrates the challenges in diagnosing CTD-ILD in patients with equivocal clinical features of a CTD, and the need for identification of pathologic variables that can support a CTD-ILD diagnosis. Importantly, we observed similar pathologic findings in patients with clear CTD diagnoses compared with patients meeting criteria for IPAF, which was recently proposed as a potential form of ILD associated with a subtle autoimmune disorder that does not meet criteria for an established CTD.[16] Specifically, our patients meeting criteria for IPAF had about the same frequency of features compared with patients with a defined CTD-ILD, including germinal centers, high numbers of lymphoid aggregates, and a high plasma cell: lymphocyte ratio. These consistent findings suggest that our results apply to patients with and without a confident underlying CTD diagnosis.

Making a diagnosis of HP is also challenging, particularly given the absence of agreed-upon clinical criteria and recent reports that up to 60% of patients with HP lack an identifiable antigen.[19,20] This is illustrated by the poor agreement for a diagnosis of HP that exist even among experienced multidisciplinary groups ($\kappa = 0.24$)[18] and a previous study in which 43% of patients thought to have idiopathic pulmonary fibrosis according to the 2011 American Thoracic Society guidelines were reclassified as HP after follow-up and careful reevaluation.[21] These challenges indicate a clear need for identification of pathologic features that suggest HP and incorporation of these features into clinical prediction tools that can provide an accurate diagnosis of HP.[22]

We identified several quantitative pathologic features that may help distinguish HP and CTD-ILD. These features are easy to measure and have the advantage of potentially reducing interobserver variability and being more reliable than more subjective findings. Measuring the dichotomous variables (germinal centers, peribronchiolar metaplasia) and determining the fraction of bronchioles showing peribronchiolar metaplasia is straightforward. Although we determined the plasma cell: lymphocyte ratio from morphometric point counting data, this can be done accurately at high power by simply comparing the absolute number of each cell type while taking care to avoid lymphoid aggregates. Measurement of pathologic features/tissue area in the biopsy (eg, number of foci of peribronchiolar metaplasia/cm^2) is more time consuming, but is simple to perform. Very fibrotic biopsies will not collapse and the volume of such biopsies is not much changed by inflation; however, biopsies with relatively little fibrosis may collapse if not inflated and we therefore recommend inflation of the biopsy with fixative and allowing to fix overnight.[23] Collapsed samples are not suitable for areal measurements, although they can still be used for evaluation of dichotomous variables, the number of bronchioles with peribronchiolar metaplasia, and plasma cell: lymphocyte ratios.

In summary, our results show that there is no single pathologic feature that clearly distinguishes chronic HP and CTD-ILD; however, the quantitative results presented here provide some guidance as to which features should be incorporated into a gestalt impression. The lack of specific diagnostic pathologic features indicates the importance of a detailed review of imaging and clinical findings for patients with fibrosing interstitial pneumonias and preferably a multidisciplinary approach and a consensus ILD diagnosis.

Ideally our findings should be tested in a validation cohort, both for accuracy and to avoid potential incorporation bias. Unfortunately we do not have such a cohort available. As the parameters we examined here were not specifically used for our multidisciplinary group diagnoses, and as we examined the cases blinded to both the original pathologic diagnoses and the multidisciplinary group diagnoses, we believe the risk of incorporation bias is low. Nonetheless, additional research is needed to validate these findings and test their reproducibility in other centers and clinical settings, as well as to identify potential clinical prediction tools that incorporate these pathologic features to allow assignment of a confident multidisciplinary diagnosis.

REFERENCES

1. Raghu G, Rochwerg B, Zhang Y, et al. American Thoracic Society; European Respiratory Society; Japanese Respiratory Society; Latin American Thoracic Association. An Official ATS/ERS/JRS/ALAT Clinical Practice Guideline: treatment of idiopathic pulmonary

Copyright © 2017 Wolters Kluwer Health, Inc. All rights reserved.

Copyright © 2017 Wolters Kluwer Health, Inc. All rights reserved.

fibrosis. An update of the 2011 Clinical Practice Guideline. *Am J Respir Crit Care Med*. 2015;192:e3–e19.
2. Tashkin DP, Roth MD, Clements P, et al. Sclerodema Lung Study II Investigators. Mycophenolate mofetil versus oral cyclophosphamide in scleroderma-related interstitial lung disease (SLS II): a randomised controlled, double-blind, parallel group trial. *Lancet Respir Med*. 2016;4:708–719.
3. Tashkin DP, Elashoff R, Clements PJ, et al. Scleroderma Lung Study Research Group. Cyclophosphamide versus placebo in scleroderma lung disease. *N Engl J Med*. 2006;354:2655–2666.
4. Morisset J, Johannson KA, Vittinghoff E, et al. Use of mycophenolate mofetil or azathioprine for the management of chronic hypersensitivity pneumonitis. *Chest*. 2017;151:619–625.
5. Fernández Pérez ER, Swigris JJ, Forssén AV, et al. Identifying an inciting antigen is associated with improved survival in patients with chronic hypersensitivity pneumonitis. *Chest*. 2013;144:1644–1651.
6. Travis WD, Costabel U, Hansell DM, et al. ATS/ERS Committee on Idiopathic Interstitial Pneumonias. An official American Thoracic Society/European Respiratory Society statement: update of the international multidisciplinary classification of the idiopathic interstitial pneumonias. *Am J Respir Crit Care Med*. 2013;188:733–748.
7. Churg A, Muller NL, Flint J, Wright JL. Chronic hypersensitivity pneumonitis. *Am J Surg Pathol*. 2006;30:201–820.
8. Takemura T, Akashi T, Kamiya H, et al. Pathological differentiation of chronic hypersensitivity pneumonitis from idiopathic pulmonary fibrosis/usual interstitial pneumonia. *Histopathology*. 2012;61:1026–1035.
9. Churg A, Sin DD, Everett D, et al. Pathologic patterns and survival in chronic hypersensitivity pneumonitis. *Am J Surg Pathol*. 2009;33:1765–1770.
10. Akashi T, Takemura T, Ando N, et al. Histopathologic analysis of sixteen autopsy cases of chronic hypersensitivity pneumonitis and comparison with idiopathic pulmonary fibrosis/usual interstitial pneumonia. *Am J Clin Pathol*. 2009;131:405–415.
11. Larsen BT, Smith ML, Elicker BM, et al. Diagnostic approach to advanced fibrotic interstitial lung disease: bringing together clinical, radiologic, and histologic clues. *Arch Pathol Lab Med*. 2016. [Epub ahead of print]. Doi:10.5858/arpa.2016-0299-SA. PubMed PMID: 27628326.
12. Myers JL. Hypersensitivity pneumonia: the role of lung biopsy in diagnosis and management. *Mod Pathol*. 2012;25(suppl 1):S58–S67.
13. Miller MR, Hankinson J, Brusasco V, et al. ATS/ERS Task Force. Standardisation of spirometry. *Eur Respir J*. 2005;26:319–338.
14. Macintyre N, Crapo RO, Viegi G, et al. Standardisation of the single-breath determination of carbon monoxide uptake in the lung. *Eur Respir J*. 2005;26:720–735.
15. Gundersen HJG, Osterby R. Optimizing sampling efficiency in stereological studies in biology: or "Do more less well!". *J Microsc*. 1981;121:65–73.
16. Fischer A, Antoniou KM, Brown KK, et al. ERS/ATS Task Force on Undifferentiated Forms of CTD-ILD. An official European Respiratory Society/American Thoracic Society research statement: interstitial pneumonia with autoimmune features. *Eur Respir J*. 2015;46:976–987.
17. Wang P, Jones KD, Urisman A, et al. Pathological findings and prognosis in a large prospective cohort of chronic hypersensitivity pneumonitis. *Chest*. 2017. [Epub ahead of print]. pii: S0012-3692(17)30220-9. Doi:10.1016/j.chest.2017.02.011. PubMed PMID: 28223152.
18. Walsh SL, Wells AU, Desai SR, et al. Multicentre evaluation of multidisciplinary team meeting agreement on diagnosis in diffuse parenchymal lung disease: a case-cohort study. *Lancet Respir Med*. 2016;4:557–565.
19. Salisbury ML, Myers JL, Belloli EA, et al. Diagnosis and treatment of fibrotic hypersensitivity pneumonia. Where we stand and where we need to go. *Am J Respir Crit Care Med*. 2016. [Epub ahead of print]. Doi:10.1164/rccm.201608-1675PP. PubMed PMID: 28002680.
20. Mooney JJ, Elicker BM, Urbania TH, et al. Radiographic fibrosis score predicts survival in hypersensitivity pneumonitis. *Chest*. 2013; 144:586–592.
21. Morell F, Villar A, Montero MÁ, et al. Chronic hypersensitivity pneumonitis in patients diagnosed with idiopathic pulmonary fibrosis: a prospective case-cohort study. *Lancet Respir Med*. 2013;1: 685–694.
22. Churg A, Ryerson CJ. The many faces of hypersensitivity pneumonitis. *Chest*. 2017. In press.
23. Churg A. An inflation procedure for open lung biopsies. *Am J Surg Pathol*. 1983;7:69–71.

Copyright © 2017 Wolters Kluwer Health, Inc. All rights reserved.

Copyright © 2017 Wolters Kluwer Health, Inc. All rights reserved.